

BRAIN TUMORS**Intraoperative Ultrasound Guidance in the Surgical Management of Choroid Plexus Papillomas:****A Case Report and Review of Literature****Atroune L., Hachid A., Hamia F., Djouadi Y., Sellami A.***Neurosurgery Department, Mustapha Pacha University Hospital Center - Algiers, Algeria***ABSTRACT:**

Choroid plexus papillomas (CPPs) are rare tumors of the central nervous system, typically benign but necessitating surgical intervention. We present the case of a six-month-old female infant with signs of intracranial hypertension, diagnosed with tetraventricular hydrocephalus and a left intraventricular mass. Emergency ventriculoperitoneal shunt valve placement was followed by brain MRI revealing a multilobulated hypodense intraventricular mass with homogeneous contrast enhancement. The patient underwent total excision of the lesion aided by intraoperative ultrasound, resulting in uneventful postoperative recovery. CPPs present unique challenges due to their vascularity and localization. Intraoperative ultrasound guidance proves invaluable in distinguishing pathological tissue, enhancing resection rates, and improving overall surgical outcomes. This case highlights the efficacy of intraoperative ultrasound in CPP management, underscoring its role as a valuable adjunct in neurosurgical practice.

Key words: *Intraoperative ultrasound Surgical guidance Choroid plexus papillomas (CPP) Pediatric neurosurgery Hydrocephalus*

INTRODUCTION:

Choroid plexus papillomas (CPPs) are uncommon tumors that arise from the epithelium of the choroid plexus within the central nervous system. Despite their typically benign nature, CPPs pose significant clinical challenges, especially in pediatric cases. Associated with symptoms such as intracranial hypertension and hydrocephalus, CPPs require timely diagnosis and intervention to prevent potential neurological complications. Here, we present a case study detailing the clinical presentation, diagnostic assessment, surgical intervention, and postoperative progress of a six-month-old female infant diagnosed with a choroid plexus papilloma. Through this case, we aim to highlight the complexities involved in managing CPPs in pediatric patients and emphasize the importance of utilizing multimodal imaging and intraoperative techniques to optimize patient outcomes.

CASE REPORT :

The case pertains to a six-month-old female infant with an unremarkable medical history who presented with symptoms suggestive of intracranial hypertension. Upon conducting a brain CT scan, findings revealed tetraentricular hydrocephalus along with the presence of a left intraventricular mass. In response, emergency intervention was initiated, and a ventriculoperitoneal shunt valve was promptly placed to alleviate the hydrocephalic pressure.

Subsequent brain MRI imaging as depicted in **(Figure 01)** delineated a complex multilobulated hypodense intraventricular mass characterized by irregular contours, further accentuated by homogeneous contrast enhancement.

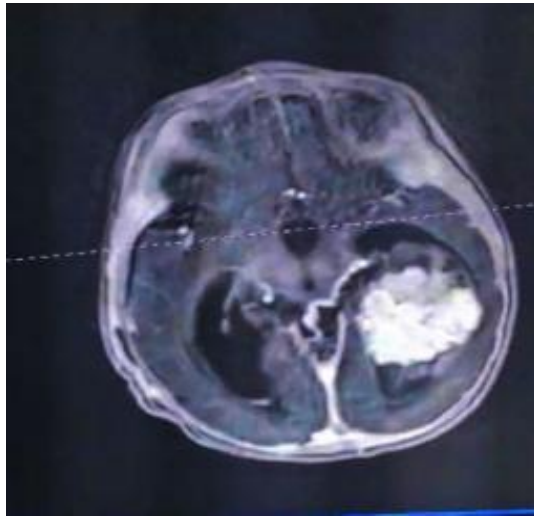


Figure 01 : An MRI image showing the lesion on the contrast-enhanced T1-weighted sequence.

Following a thorough evaluation and preparation, the patient was admitted to the operating theater, where she underwent a comprehensive excision procedure of the lesion. This surgical intervention was facilitated through a meticulous trans-temporal approach, involving the creation of a temporal bone flap (**Figure 02**).

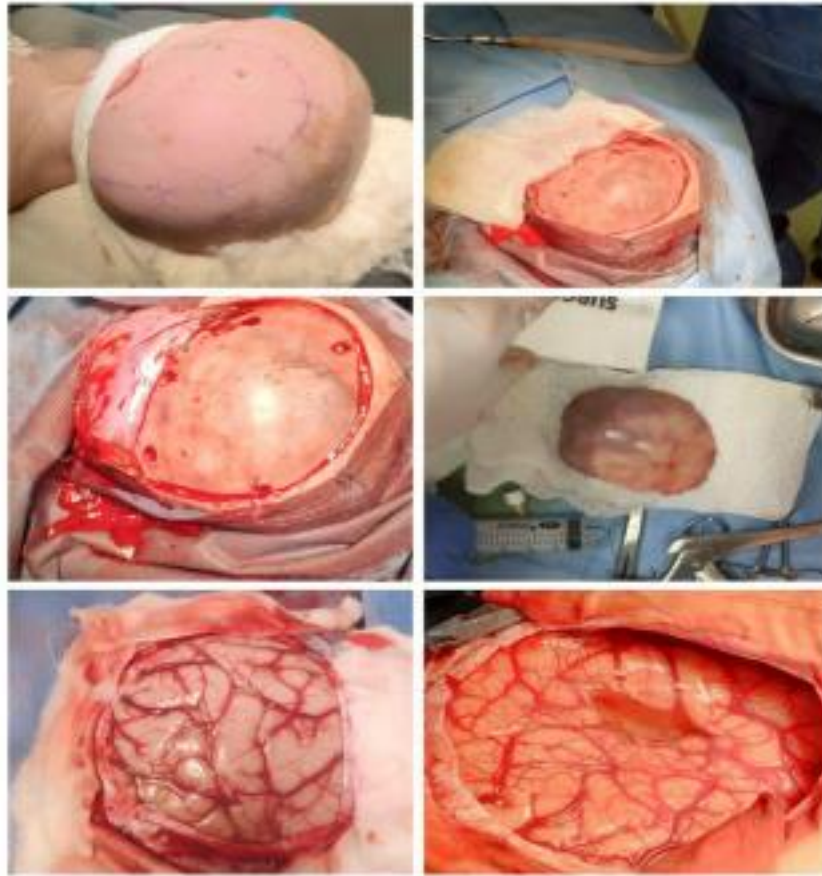

Figure 02 : Intraoperative images illustrating the various stages of the surgical approach.

The procedure was further aided by the utilization of an optical microscope as illustrated in **(Figure 03)** and intraoperative ultrasound guidance as depicted in **(Figure 04)**, ensuring precision and accuracy throughout the resection process**(Figure 05)**. Remarkably, the postoperative period was marked by an uneventful recovery trajectory, culminating in the patient's discharge on the 10th day post-surgery.

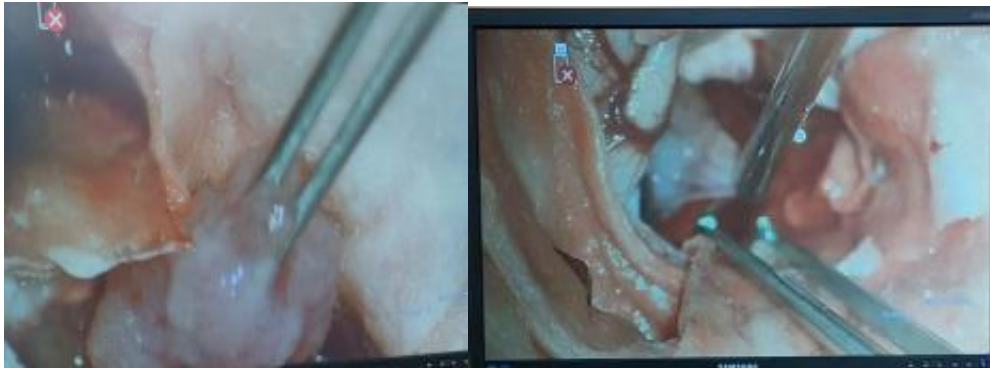
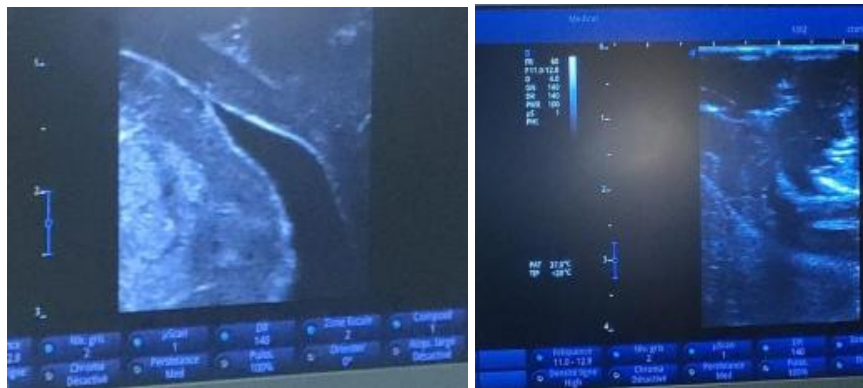
Figure 03 : Intraoperative images under the microscope showing the lesion.



A

B

Figure 04 : Intraoperative ultrasound image.

(A) : Before the excision of the lesion (B) : After the excision of the lesion

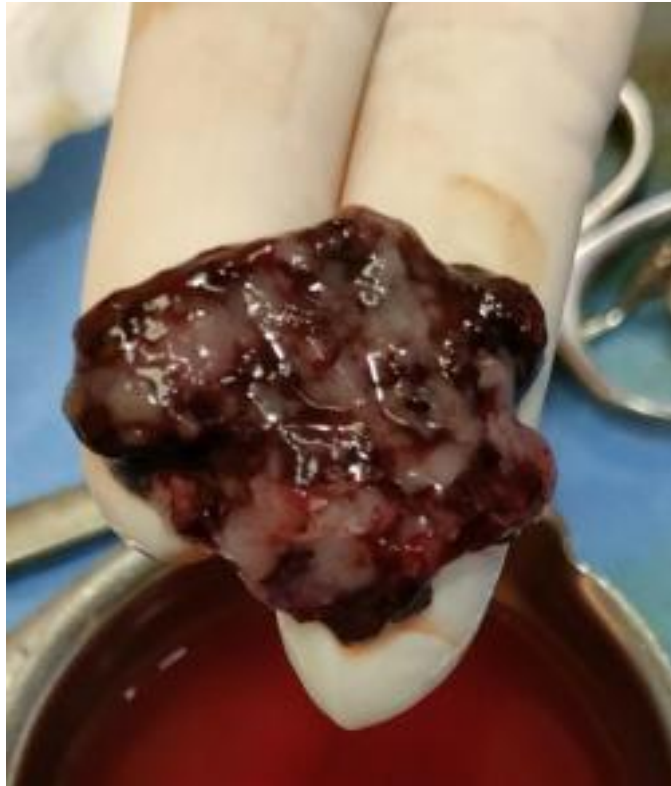

Figure 05 : Intraoperative image of the lesion.

DISCUSSION :

Choroid plexus papillomas (CPPs) are rare tumors of the central nervous system, classified as WHO grade I. They can occur at any age but are more common in infants, with their site of occurrence varying depending on age. Typically, they present with increased head circumference or changes in mental status in children, while in adults, they manifest as signs of increased intracranial pressure⁽⁰¹⁾. Imaging reveals enhanced intraventricular masses. Surgery is the treatment of choice for these lesions, despite their benign nature, they have a good prognosis, thanks to advancements in surgical techniques and intensive care.

Studies have shown an association between simian virus (SV) 40 and the development of choroid plexus tumors (CPTs), with other viruses like BK and JC viruses also implicated. Additionally, the association of large T antigen with tumor suppressor proteins p53 and pRb has been demonstrated in humans with choroid plexus tumors. Epidemiologically, CPPs are rare neuroectodermal tumors, constituting the third most common congenital brain tumors in the pediatric population.

Pathologically, according to the WHO classification, they are classified as papillomas (grade I), atypical tumors (grade II), and carcinomas (grade III). CPPs typically have less than two

mitotic figures per 10 high-power fields, with papillomas being less aggressive than atypical tumors and carcinomas. Immunohistochemically, CPPs exhibit positivity for cytokeratin, vimentin, podoplanin, and S-100, with occasional positivity for glial fibrillary acidic protein (GFAP), especially in older patients. CPPs can also be associated with syndromes like Aicardi syndrome, hypomelanosis of Ito, and duplication 9p.

Clinically, CPPs mainly present with intracranial hypertension due to hydrocephalus and focal neurological symptoms such as headaches, vomiting, epilepsy, and abnormal gait(04). Physical examination typically shows an enlarged head circumference and papilledema. Imaging reveals irregular, lobulated masses, sometimes resembling a "cauliflower," with CT scans showing homogeneous iso- or slightly high-density masses, associated with calcifications, hemorrhages, and occasionally cystic degeneration, while MRI reveals iso- or slightly low signal intensity on T1WI

and iso- or slightly high signal intensity on T2WI, with intense homogeneous enhancement on contrast-enhanced MRI.

Total resection is the most effective treatment for CPP, although challenging due to the tumor's high vascularity, intraoperative hemorrhage, and potential life-threatening complications. Therefore, various therapeutic modalities have been used, including control of the vascular pedicle and rapid resection, with intraoperative ultrasound being a valuable tool to aid in surgical guidance.(06)

Intraoperative ultrasound guidance differentiates normal tissue from pathological tissue in 80 to 88% of cases and increases lesion resection by 55%. Higher rates may be observed if lesions have heterogeneous properties or cystic areas.

Intraoperative ultrasound guidance also provides vascular mapping, particularly arterial, related to the lesion and adjacent tissue. After tumor resection, it's possible to assess the presence of residual lesions in the operative field.

Ultrasound is used for resection control in many neurosurgery units worldwide. Lex et al. and Woydt et al. compared real-time 2D ultrasound images of brain tumors to histopathology, concluding that intraoperative ultrasound could improve total macroscopic resection. (05)

Chacko et al. compared 2D ultrasound images at the end of tumor resection to histopathology and found that out of 79 samples taken at the tumor-brain interface reported as tumor on ultrasound, 66 had positive tumor histopathology, yielding a positive predictive

value of 0.84.(10) The importance of maintaining good ultrasound image quality throughout the operation was also illustrated in a retrospective study of patients with glial tumors operated with 3D ultrasound imaging.

The study found a significant relationship between the resection grade and ultrasound image quality, meaning that good ultrasound image quality was associated with a higher resection grade(09). Intraoperative ultrasound guidance (iUS) is a tool that continues to improve over time in terms of image quality, accurately distinguishing between pathological and normal tissue and functioning as a real-time topographic guidance tool, making it an interesting method to consider for routine use in neurosurgery.

It can be used in any operating room, without special instrumentation or setup, and can be used without the presence of a radiologist or technician; it adds a small amount of time to the surgical procedure, and costs are considerably lower compared to neuronavigation devices and intraoperative MRI (iMRI). Known applications of intraoperative ultrasound guidance include tumor localization, resection evaluation, identification of surrounding vessels and dural sinus patency, guided aspiration of brain abscesses, and ventriculostomy. Guided tumor resection is associated with higher overall survival rates.(11)

Intraoperative MRI and neuronavigation are established and well-known techniques, but the huge costs of implementation and maintenance, along with the increased surgical duration associated with these techniques, indicate that, for now, they are unlikely to reach most neurosurgical units worldwide. Intraoperative ultrasound guidance is a technique with lower cost compared to the aforementioned iMRI and neuronavigation. Ionizing radiation is a concern with the use of the intraoperative CT scanner unit, which is spared with the use of iUS. Postoperative complications related to transducer compression against the cerebral cortex or infection rates related to iUS are not higher than those associated with the procedure itself. (13)

Ultrasound serves as a complementary tool to neuronavigation images and has been proposed for routine use in the surgery of intra- and extra-axial brain tumors, intraventricular, supra- or infratentorial tumors, and intradural spinal tumors.(14)

However, some recommendations and considerations must be taken into account. Preoperative planning correlating radiological images with craniometric landmarks or neuronavigation is crucial to ensure surgical success.

Additionally, training in ultrasound interpretation should be integrated into neurosurgery residency programs to improve surgeons' skills. Limitations of this technique include reverberation in deep lesions as well as the need for appropriate craniotomy size and adequate transducer selection. Despite these challenges, intraoperative ultrasound guided tumor resection is recommended as a surgical guidance tool, allowing for effective correlation between preoperative images and intraoperative outcomes.

CONCLUSION :

Choroid plexus papillomas (CPP) are rare tumors of the central nervous system, typically benign but requiring surgical intervention. They are associated with various viruses and can manifest as early as infancy, with a higher incidence in infants. Diagnosis relies on imaging, and their primary treatment is surgery. The use of intraoperative ultrasound provides significant benefits in real-time tumor resection, enhancing surgical outcomes.

REFERENCES :

01. Louis DN, Ohgaki H, Wiestler OD, Cavenee WK, Burger PC, Jouvet A, et al. The 2007 WHO classification of tumours of the central nervous system. *Acta Neuropathol.* 2007;114:97-109.
02. Menon G, Nair SN, Baldawa SS, Rao RB, Krishnakumar KP, Gopalakrishnan CV. Choroidplexus tumors: an institutional series of 25 patients. *Neurol India.* 2010;58:429-435.
03. Duffner PK, Cohen ME, Thomas PR, Lansky SB. The long-term effects of cranial irradiation on the central nervous system. *Cancer.* 1985;56:1841-1846.
04. Rovit RL, Schechter MM, Chodroff P. Choroidplexus papillomas. Observations on radiographic diagnosis. *Am J Roentgenol Radium Ther Nucl Med.* 1970 Nov; 110(3): 608-17.
05. Fujimura M, Onuma T, Kameyama M, Motohashi O, Kon H, Yamamoto K, et al. Hydrocephalus due to cerebrospinal fluid overproduction by bilateral choroid plexus papillomas. *Childs Nerv Syst.* 2004 Jul; 20(7): 485-8.
06. Santos MM, Souweidane MM. Purely endoscopic resection of a choroid plexus

papillomaof the third ventricle: case report. *J NeurosurgPediatr.* 2015 Jul; 16(1): 54–7.

07 Wolff JE, Sajedi M, Brant R, Coppes MJ, EgelerRM. Choroid plexus tumours. *Br J Cancer.*2002 Nov; 87(10): 1086– 91.

08 Klip H, Burger CW, de Kraker J, van LeeuwenFE; OMEGA-project group. Risk of cancer inthe offspring of women who underwent ovarianstimulation for IVF. *Hum Reprod.* 2001Nov; 16(11): 2451–8.

09 Auer LM, Van Velthoven V. Intraoperative Ultrasound Imaging inNeurosurgery, Comparison with CT and MRI. Springered.Berlin,Heidelberg1990

10 Mair R, Heald J, Poeata I, Ivanov M. A practical grading system ofultrasonographic visibility for intracerebral lesions. *Acta Neurochir(Wien)* 2013;155(12):2293–2298. Doi: 10.1007/s00701-013-1868-9

11 Gousias K, Schramm J, Simon M. Extent of resection and survivalin supratentorial infiltrative low-grade gliomas: analysis of andadjustment for treatment bias. *Acta Neurochir (Wien)* 2014;156(02):327–337. Doi: 10.1007/s00701- 013-1945-

12 Wijnenga MMJ, Mattni T, French PJ, et al. Does early resection ofpresumed low-grade glioma improve survival? A clinical perspective.*J Neurooncol* 2017;133(01):137–146. Doi: 10.1007/s11060-017-2418-8

13 Ronkainen J, Tervonen O. Cost analysis of an open low-field(0.23T)MRI unit: effect of procedure shares in combined imaging,interventional, and neurosurgical use. *Acta Radiol* 2006;47(04):359–365<http://www.ncbi.nlm.nih.gov/pubmed/16739694>

14 Sweeney JF, Smith H, Taplin A, Perloff E, Adamo MA. Efficacy ofintraoperative ultrasonography in neurosurgical tumor resection.*J Neurosurg Pediatr* 2018;21(05):504–510. Doi: 10.3171/2017.11.